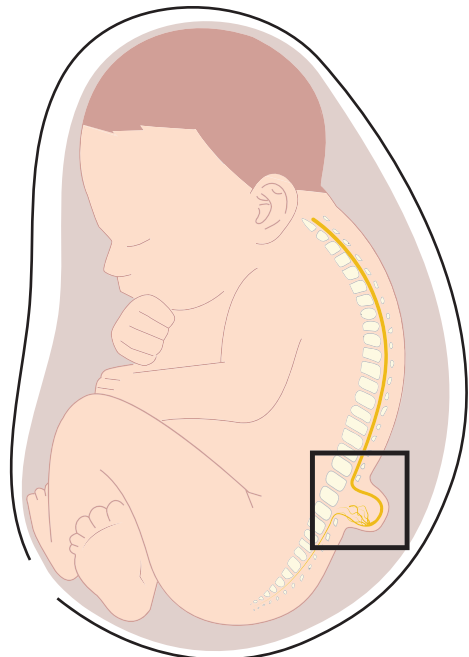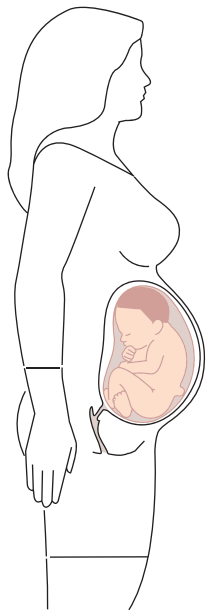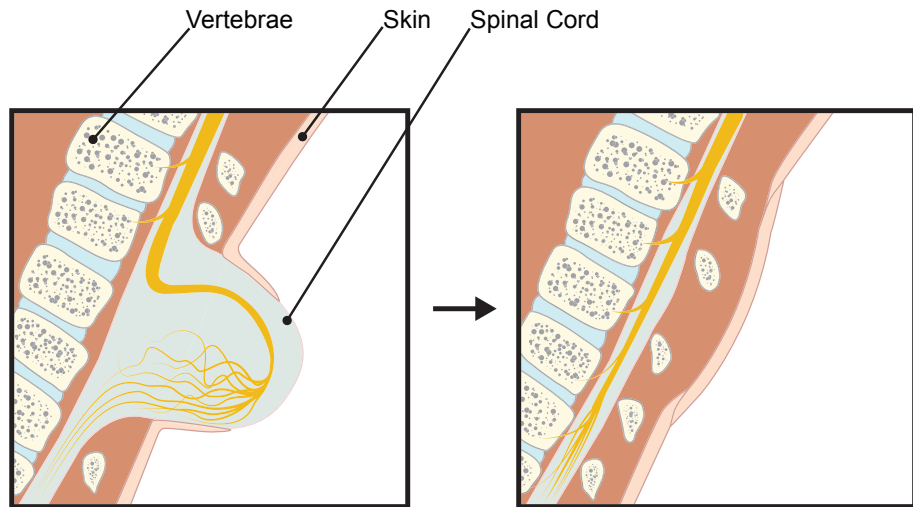


Fetus



Myelomeningocele

Post Surgery

